

Original Article

Management of Gummy Smile by Surgical and Non-Surgical Techniques: A Clinical Comparative Study

Blend A. Omer¹, Chenar A. Mohammad²

Abstract

Objective: Gummy smile (GS) also referred to an excessive gingival display (EGD). It's an aesthetic disorder that can be managed by a variety of procedures include; modified lip reposition surgery (MLRS) and botulinum toxin type-A injection (BTX-A). This study aimed to evaluate and compare the effect of treatment of GS by surgical technique (MLRS) and non-surgical technique (BTX-A injection) 1 and 4 months after treatment.

Methods: The study was conducted from November 2018 to November 2019. Forty adult patients aged 18-35 years with a EGD \geq 4 mm caused by soft tissue disorders were recruited. Patients divided into two groups; Group 1 included 20 patients treated by MLRS and Group 2 (20 patients) treated by BTX-A injection. The amount of gingival display (GD) was evaluated after 1 and 4 months of the treatments by Autodesk AutoCAD computer program. ANOVA test used to compare changes in GD before and following treatments.

Results: The study showed a significant reduction in the amount of GD in both groups after 1 and 4 months of the treatment (p value < 0.05). Non-significant differences between both groups in 1 and 4 months of follow up (p value > 0.05).

Conclusions: Both MLRS and BTX-A injection technique were effective treatment modalities for patients suffering from GS.

Keywords: Gummy smile, Gingival display, Lip reposition surgery, Botox injection.

Submitted: November 12, 2019, Accepted: December 8, 2019, Published: December 27, 2019.

Cite this article as: Omar BA, Mohammad CA. Management of Gummy Smile by Surgical and Non-Surgical Techniques: A Clinical Comparative Study. Sulaimani Dent J. 2019;6(2):59-68.

DOI: <https://doi.org/10.17656/sdj.10098>

1. MSc Student , College of Dentistry, Hawler Medical University, Erbil, Iraq.
2. Department of Periodontics, College of Dentistry, Hawler Medical University, Erbil, Iraq.

* Corresponding author: chenaranwar0@gmail.com

Introduction

Smile is the most identifiable expression in the world, the foundation of social communication and is one of the most excellent customs to express our feelings. A nice smile can perform as a powerful message tool, an unaesthetic smile can have the same powerful negative effect so, dentists all over the world are interested in achieving esthetically attractive smile⁽¹⁾.

An attractive smile would be ideally a perfect set of teeth along with good-looking peri-oral and facial esthetics. The association and relationship between three components of teeth, lip framework, and the gingival scaffold determine and control the esthetic appearance of a smile⁽²⁾. The amount of gingival appearance on smiling is very significant to smile attractiveness⁽¹⁾. The amount of GD is an important characteristic in a person's own satisfaction with her/his smile⁽³⁾. Patients with EGD are often uncomfortable and embarrassed about it and some of them are affected psychologically^(4,5)

Gingival smile is known by a variety of terms including "gummy smile, excessive gingival display, high lip line, short upper lip, and full denture smile". Possibly these variations in terms are revealing many different causes of a gummy smile⁽²⁾. More than 50% of patients have some form of gingival display in a normal smile, in absolute numbers, a normal gingival appearance between the inferior border of the upper lip and the gingival margin of the anterior central incisors during a normal smile is 1-2 mm⁽⁶⁾.

In contrast, an excessive gingival display to lip distance of 4 mm or more is classified as unpleasant and unattractive by laypeople and dentists⁽⁷⁾. EGD may be due to several etiological factors including; hypermobile upper lip (HUL), altered passive eruption (APE), short upper lip (SUL), vertical maxillary excess (VME)⁽⁸⁻¹⁰⁾ and plaque/drug-induced gingival enlargement (DIGE)⁽¹⁰⁾. Options of treatment plan vary completely according to each cause(s) ranging from simple gingivectomy procedure, osseous surgery, myectomies to detach the smile muscle attachment^(10,11), lip repositioning surgery alone or in combination with rhinoplasty⁽¹¹⁾, and orthognathic surgery for correction of jaw deformities⁽¹²⁾.

Lip repositioning is a surgical technique which is performed by removing a strip of mucosa from maxillary buccal vestibule and creating a partial-thickness flap between mucogingival junction and upper lip musculature, and suturing the lip mucosa with mucogingival junction, resulting in a shallow vetibular restricting of the muscle pull; thereby reducing EGD⁽¹³⁾. More recently, Botulinum toxin type-A injection (Botox

injection BT) has been introduced in dental literature⁽¹⁴⁾. The use of BT is particularly effective in managing cases of excessive gingival display due to excessive contraction of upper lip muscles, and primarily levator labii superioris alaeque nasi^(4,15). A study reported that BTX-A injection exhibits better results than those of surgery and had given safer and more satisfactory results than lip reposition⁽¹⁶⁾.

To the best of our knowledge, it's the first study in Iraq conducted to evaluate the effect of different treatment modalities; one by surgical technique (Modified lip reposition surgery) and other by non-surgical technique (Botulinum toxin type A injection) on excessive gingival display.

Patients and method

Study Samples

This study performed in the Department of Periodontology / College of Dentistry / Hawler Medical University / Erbil city, from November 2018 to November 2019. This clinical comparative study conducted on 40 patients with an excessive gingival appearance with ≥ 4 mm gingival appearance, of both sexes, they were divided randomly into two groups, group 1 (MLRS group) included 20 patients were treated by surgical MLRS and the group 2 (BTX-A injection group) included 20 patients treated by non-surgical technique using BTX-A injection, Botox (Allergan).

Medical histories of all patients were recorded at the time of examination in a special recording form for making a checklist for inclusion and exclusion criteria for the study. The inclusion criteria included: gingival display of at least 4 mm when smiling, lip mobility ≥ 8 mm, age ranged from 18-35 years old, co-operative and motivated patients with good oral hygiene and non-smokers, patients have no history of bruxism or parafunctional habits, patients free from any systemic diseases, patients complained from a soft tissue disorders (short upper lips (SUL) and hypermobile upper lip (HUL) or combination of them were included in this study and were treated either by MLRS or BTX-A injection. Exclusion criteria included: patients with uncontrolled systemic diseases that may interfere with surgical intervention, patients with poor oral hygiene, patients with stage 4 plus grade C periodontitis, patients with asymmetrical smile (gummy smile), patients with inadequate width of attached gingiva, pregnant or lactating females, presence of infection or inflammation at the site of proposed incision or injection, psychologically unstable patients and patients with severe skeletal anomalies like severe vertical maxillary excess (VME > 8 mm of gingival display)^(7,17). Additional exclusion criteria for botulinum injection

included^(2,18): patients with hypersensitivity or allergies to Botulinum toxin, human albumin or saline solution, patients with motor neuropathy, neuromuscular disorders such as myasthenia gravis, multiple sclerosis, muscular dystrophy, Lambert-Eston syndrome, amyotrophic lateral sclerosis etc. and patients taking certain medications that can interfere with neuromuscular impulse transmission and potentiate the effect of BOTOX (e.g. aminoglycoside antibiotics, quinine, penicillamine, and calcium channel blockers).

The study protocol was approved by the institutional ethical committee of the College of Dentistry/Hawler Medical University and the written consent form was signed by all patients before the conduction of the study.

Patient examinations and measurements

For each patient photographical pictures were taken by (Nikon 1300D digital camera with 105 mm micro lens Sigma type) through frontal smile view/close up smile view, this view have been taken when patient seated comfortably on a chair in relaxed position, looking straight with Frankfurt Horizontal plane (FH) parallel to the floor⁽¹⁸⁾. The patient was asked to give a broad smile with teeth, preferably in occlusion and avoid wide-open mouth, with focusing on the exposed teeth as it is the focal point. Then clinical measurements were taken before treatment and at 1 and 4 months after treatment by millimeter ruler and Autodesk AutoCAD Civil 3D 2018 computer program, these following measurements were taken at rest and/or at maximum smile on clinical. Total lip length was measured from the base of the nose to the inferior border of the upper lip vermilion, anterior gingival display was measured from the most inferior portion of the upper lip vermilion to the gingival margin of the right maxillary central incisor⁽¹⁹⁾, posterior gingival display was also measured from the most inferior portion of the upper lip vermilion to the gingival margin on the right maxillary first/second premolars⁽²⁰⁾, Internal lip length (=vestibular depth) was measured with a commercially available millimeter ruler (internal lip length measurement was only recorded at rest). Lip mobility was measured or calculated by subtracting the incisal exposure at rest from the dento-gingival exposure during maximum smile⁽²¹⁾.

Modified lip reposition surgery procedure

Local anesthesia (xylocaine 2% with epinephrine 1:80,000) was administered at the vestibular mucosa and lip from the maxillary right to left first molar. The surgical site was marked with an indelible pencil. Then

a partial-thickness incision was made at the mucogingival junction from the mesial line angle of the right central incisor to the mesial line angle of the right first molar, then a second partial-thickness incision parallel to the first incision and 10-12 mm apical to the mucogingival junction was made in the labial mucosa. Then the incisions were connected at the central incisor region without involving labial frenum and at the right first molar region creating a quadrilateral outline. The epithelium was then dissected within this outline leaving the underlying connective tissue exposed, the same procedure was carried out on the left side as well⁽²⁰⁾ as shown in Figure 1. Then the parallel incisions were connected with interrupted stabilization sutures (5/0) polyglycolic acid sutures (PGA) and the area was covered by pressure pack. Nonsteroidal anti-inflammatory drug (diclofenac sodium 50 mg three times daily for 3 days) and oral antibiotics (amoxicillin 500 mg three times daily for 5 days) were prescribed for each patient, and patients were instructed to apply ice pack postoperatively and to minimize lip movement for a week. Sutures were removed after 2 weeks and patient was recalled after 1 and 4 months of treatment.

Botulinum toxin type A preparation

Before reconstitution, the rubber seal of the vial should be wiped with an alcohol swab, a 3mL syringe with a 25-gauge needle was used to inject the desired volume of normal saline solution into the vial, the vial was rotated during saline's injection to assist a gentle reconstitution. BTX-A was diluted according to the manufacturer's recommendations by adding 2ml of 0.9% normal saline solution without preservations to 100 units of vacuum-dried BTX-A which results in a concentration of 5 U/ 0.1 ml⁽⁴⁾.

Botulinum toxin type A injection procedure

The injection sites were determined by muscle stimulation (smiling) and palpation on contraction to ensure accurate muscle location before injection⁽⁴⁾. Under sterile condition, aspiration was done to avoid involuntary deposition of the toxin into the facial arteries, the point of injection (Yonsei point) was marked on each side located 1cm away from the ala of the nose and 3cm away from the lip, then 2.5 units were intramuscularly injected at each Yonsei point using 1

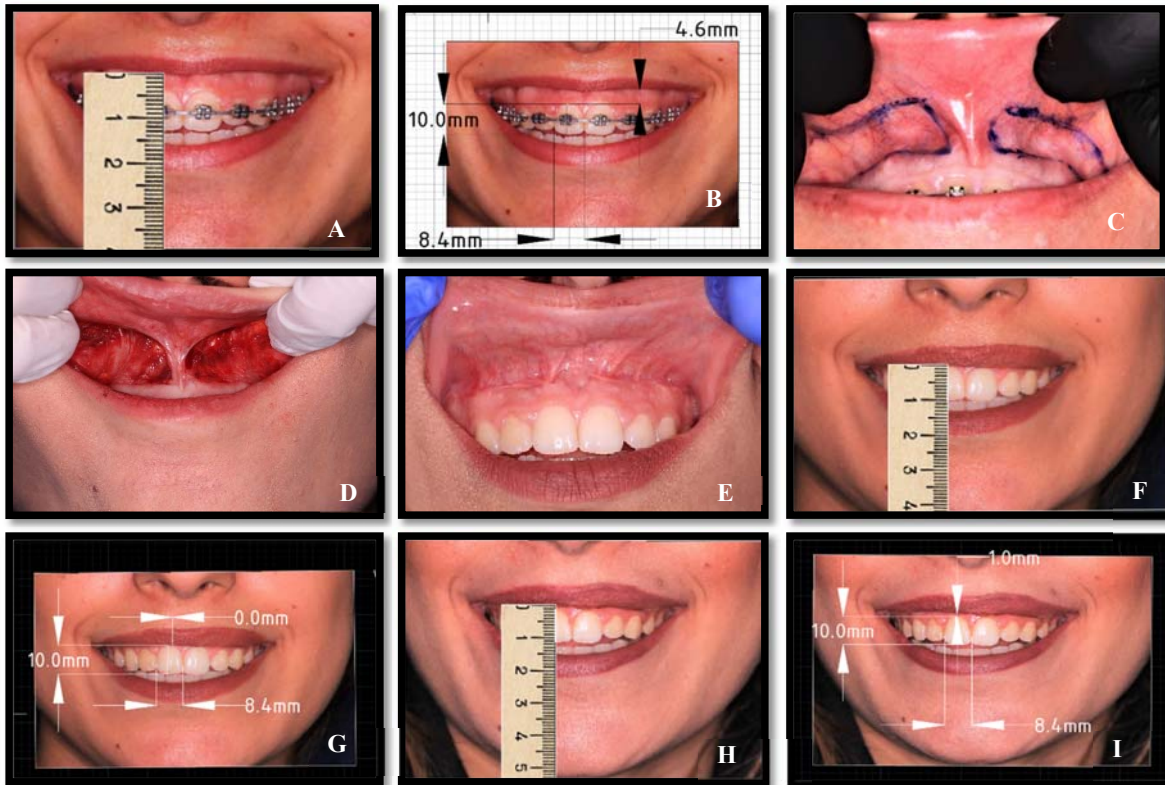

Figure 1: 20 years old ,with 4.6 mm of GD at full smiling, treated by modified lip reposition surgery and the steps includes : **A**, measurement of GD by millimeter ruler. **B**, measurement of GD by using a computer program (Autodesk, AutoCAD Civil 3D 2018) GD= 4.6 mm. **C**, Borders of the surgical area to be excised were demarcated with the preservation of midline frenum. **D**, Removal of the outlined mucosa exposing the underlining connective tissue. **E**, 1 month after suture removal and healed the surgical area. **F**, 1 month after surgical procedure GD measured by millimeter ruler. **G**, 1 month after surgical procedure GD measured by (Autodesk, AutoCAD) GD = 0.0 mm. **H**, 4 months after surgical procedure GD measured by millimeter ruler. **I**, 4 months after surgical procedure GD measured by (Autodesk, AutoCAD) GD = 1.0 mm.

mL insulin as shown in Figure 2. The patient was instructed to avoid laser/IPL treatments, facials and facial massage for one to two weeks after injections to minimize toxins dislodging and traveling to the surrounding muscles and instructed to not use aspirin, ibuprofen or naproxen⁽¹⁸⁾. The patient was re-evaluated after 1 month and 4 months of treatment.

Statistical analysis

The data were statistically analyzed using Statistical Package for Science Services SPSS (version 24: SPSS Inc., Chicago, IL, USA). ANOVA test used to compare changes in GD at base line, 1 month and 4 months, dependent t-test (Paired –samples t test) used to compare scores of two different variables for the same group and independent t-test used to compare scores of the same variable between two groups. P value ≤ 0.05 was regarded as statistically significant.

Results

Forty patients with the mean age 27.2 ± 5.2 years old and GD ≥ 4 mm were included in the study. For the MLRS group, the mean age was 26 ± 5.2 years and for the BTX-A group, the mean age was 28.4 ± 5.2 years. In general, in group 1 which was treated by surgery, patients were complained in the early phase of healing from “tension feeling” circumorally, predominantly in the upper lip. Two patients complained from blood oozing through suture in the initial days of the surgery, seven patients expressed edema at a moderate rate but this disappeared within a week, and three patients reported perioral edema extending to the lower eyelids accomplished by ecchymosis last for 2 weeks. For the group 2 which was treated by BTX-A injection, patients complained of pain at the injection site and itching of the injected area.

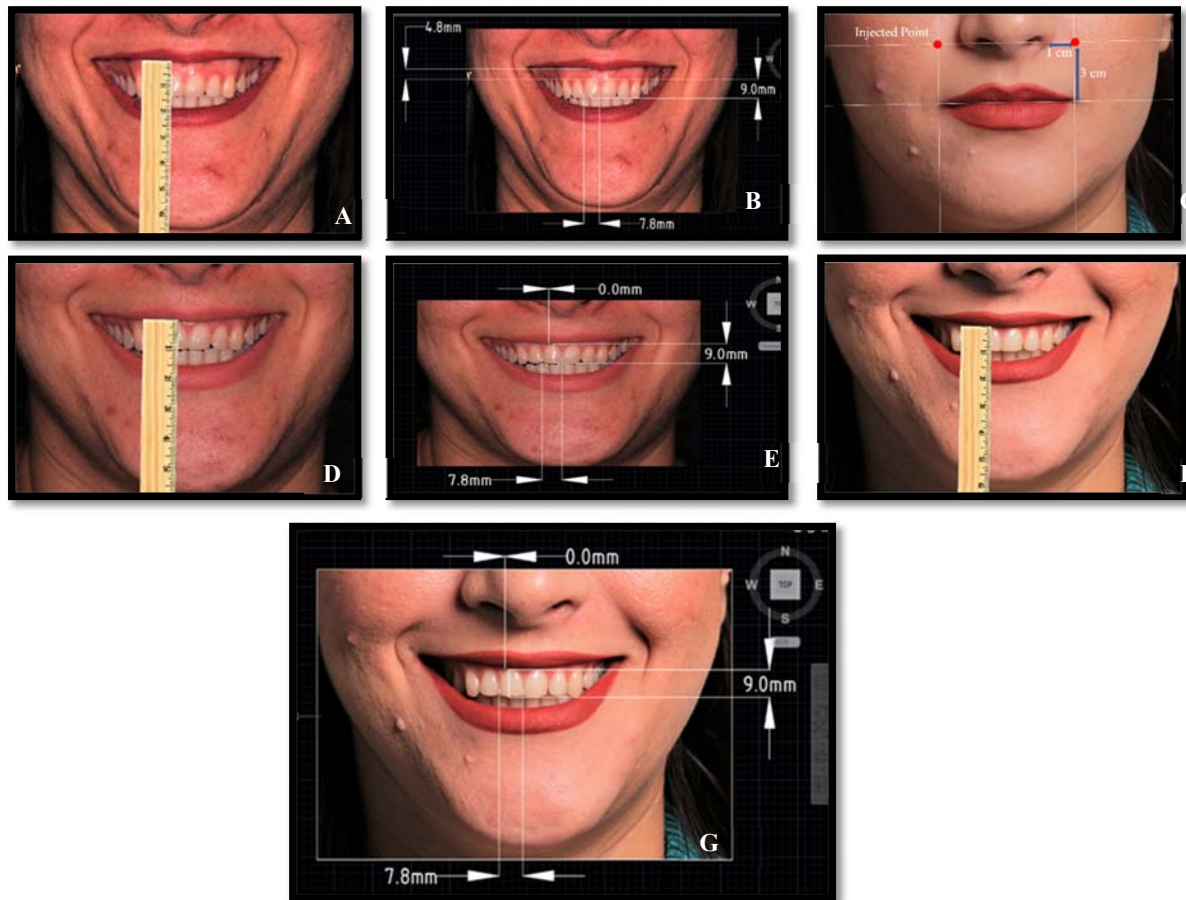


Figure 2: 28 years old with 4.8 mm of GD at full smiling, treated by non-surgical approach (Botulinum toxin type A injection) and the steps includes: **A**, measurement of GD with a millimeter ruler. **B**, measurements of GD by using a computer program (Autodesk, AutoCAD Civil 3D 2018) GD= 4.8 mm. **C**, BTX-A injection points. **D**, measurement of GD after 1 month by millimeter ruler GD= 0.0 mm **E**, measurement of GD after 1 month by using a computer program (Autodesk, AutoCAD Civil 3D 2018) GD= 0.0 mm. **F**, measurement GD after 4 months by millimeter ruler. **G**, measurement of GD after 4 months by using computer program (Autodesk, AutoCAD Civil 3D 2018).

Gender and types of a gummy smile

All participants of the MLRS group and 95% of the BTX-A group were female. The types of gummy smiles were equal in both groups: 55% of both groups had anterior, 30% mixed and 15% posterior types. Regarding age, gender and type of GS the differences between both groups were not statistically significant as shown in Table 1 (p value > 0.05).

Gingival display before and after therapy

For GD in MLRS group the mean value at baseline (before treatment) was 4.88 ± 1.04 mm then decreased to 0.40 ± 0.55 mm after one month of treatment and slightly increased to 1.31 ± 0.62 mm after four months

of surgery, these changes were statistically significant in all study time points (base line and 1 month ,base line and 4 months ,1 and 4 months) as shown in table 3 (p value = 0.001). While for the BTX-A injection, the mean value of GD at baseline (before treatment) was 4.67 ± 0.88 mm which significantly decreased to 0.52 ± 0.48 mm after one month of injection, then slightly increased to 1.61 ± 0.77 mm after four months of injection, these changes were statistically significant in all study time points (base line and 1 month ,base line and 4 months,1 and 4 months) as shown in Figure 3 (p value = 0.001). For comparison between two groups, the results showed that there was no statistically significant difference between MLRS and BTX-A groups regarding gingival display GD at baseline, 1 month and 4 months after therapy as shown in Table 2 (p value > 0.05) (independent t-test). ANOVA test was done to compare

average changes of GD at different times (base line, 1 month and 4 months) for MLRS group and BOTX-A

groups and the changes were statistically significant and p value was 0.001 (Table 3).

Table 1: Gender and type of GS for MLRS and BTX-A groups.

Variables	Categories	Study group		Total
		MLRS	BTX-A	
Gender	Female	20 (100%)	19 (95%)	39 (97.5%)
	Male	0 (0%)	1 (5%)	1 (2.5%)
Type of GS	Anterior GS	11 (55%)	11 (55%)	22 (55%)
	Posterior GS	3 (15%)	3 (15%)	6 (15%)
	Mix GS	6 (30%)	6 (30%)	12 (30%)
Total		20 (100%)	20 (100%)	40 (100%)

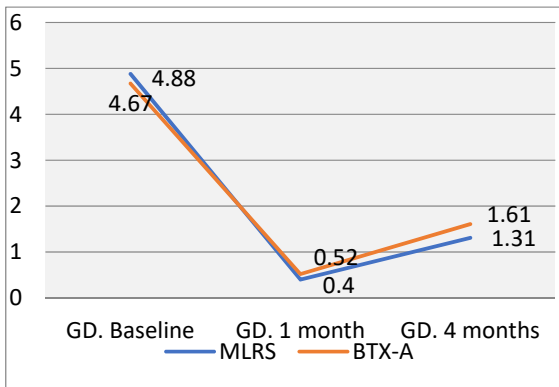


Figure 3: Comparison between GD measurements of both study groups.

Table 2: Comparison between MLRS &BTX-A injection groups in relation to GD measurements.

	Time	Study groups	N.	Mean ± S. D	p-value
GD mm	Before	MLRS	20	4.88 ± 1.04	0.49
		BTX-A	20	4.67 ± 0.88	
	1 month	MLRS	20	0.40 ± 0.55	0.45
		BTX-A	20	0.52 ± 0.48	
	4 months	MLRS	20	1.31 ± 0.62	0.17
		BTX-A	20	1.61 ± 0.77	

Table 3. ANOVA test to compare changes in GD before and following treatments in MLRS and BTX-A groups.

Groups	Times	N.	Mean	S.D.	Minimum	Maximum	Sig.
MLRS	Baseline	20	4.88	1.04	3.7	7.8	0.001
	1 month	20	.40	.55	.0	1.8	
	4 month	20	1.31	.62	.0	2.4	
	Total	20	2.19	2.09	.0	7.8	
BTX-A	Baseline	20	4.67	.88	3.50	7.10	0.001
	1 month	20	.52	.48	.00	1.50	
	4 month	20	1.61	.77	.00	2.80	
	Total	20	2.27	1.91	.00	7.10	

Discussion

The normal gingival appearance between the lower border of the upper lip and the gingival margin of upper anterior central incisors during a normal smile is about 1-2 mm⁽⁶⁾, Kokich et al⁽⁷⁾ reported that ≥ 4 mm of GD classified as “unattractive” by laypeople and general dentists, while Allen⁽²²⁾, Graber and Salama⁽⁸⁾, Simon and Rosenblatt⁽⁶⁾ diagnosed cases with ≥ 3 mm of GD to have a GS. Therefore, in our study patients with ≥ 4 mm of GD were diagnosed to have a GS. All participants of the MLRS and 95% of the BTX-A injection groups were females, to avoid any differences in the result of the variability in the muscle volume between genders, in general males have a large muscle volume than females^(23,24).

The reason for selecting treatment of GS by two different techniques is that some authors revealed that EGD caused by SUL can be corrected by lip repositioning surgery^(6,25,26,27), other authors reported that lip repositioning surgery was an option for correction of EGD caused by HUL^(13,27,28). While other studies reported that BTX-A has been used as a treatment option for correction of EGD in cases of SU⁽²⁹⁾, and HUL^(4,5,30-32). In our study, lip repositioning surgery technique was conducted with a modification of leaving the midline maxillary labial frenum intact to prevent the midline being shifted, and to avoid the morbidity associated with the removal of maxillary labial frenum, similar to many authors^(20,23,34-37) and accomplished by excision of 10-12 mm of the upper labial mucosa similar to the technique explained by Litton and Fournier⁽²⁵⁾ and Rosenblatt and Simon^(6,26). For GD in group 1, the results showed that the mean value of GD at baseline was 4.88 ± 1.04 mm which decreased to 0.40 ± 0.55 mm after one month, then

after four months of surgery, a slight increase in the mean value of GD 1.31 ± 0.62 mm was noticed but still with significant differences with baseline. This slight increase may be due to the beginning of muscle reattachment to its previous place which may be explained by hypertonic muscle. Our results are similar to other studies^(26,27,35-37), Grover et al⁽²⁷⁾ and Gaddale et al⁽²⁹⁾ reported that the reduction in the mean value of GD at a year follow up, another studies by Sanchez et al⁽³⁷⁾ and Ribeiro-Junior et al⁽³⁶⁾ showed that the reduction in the amount of GD and the new lip position were stable at 6 months after surgery, furthermore, Mantovani et al⁽³⁵⁾ reported a reduction in the amount of GD at 9 months of follow up. In contrast to our result^(24,38), Litton and Fournier⁽²⁵⁾ and Humayun et al⁽³⁸⁾ reported complete relapse after lip repositioning surgery. Bhola et al⁽⁹⁾ reported that unilateral or bilateral relapse might be seen within 6 to 8 weeks after surgery with the occurrence of asymmetric smile. These variations in the results may be due to the limited duration of the study, sample size, and till now there is no study reported more than one year of follow up and long term stability of lip repositioning surgery⁽³⁵⁾.

For patients in group 2 in which GS was corrected by BTX-A injection in “Yonsei Point” on both right and left sides of the nostrils⁽⁵⁾. This point had been proposed and proved as an effective in several clinical applications by many authors^(2,29,39), while others proposed additional intra-muscular point of injection at the labial component of LLSAN muscle on both sides and patient was injected with a dose of 1.25 u/0.1ml as a baseline in right and left sides⁽²⁹⁾ or a dose of 2.5U/0.1ml for each point as reported by Polo in 2008⁽⁴⁾. In our study, the selected dose of BTX-A injection on each side was 2.5 U/0.1 ml, which was proven to be the least dose to give a

maximum effect and to avoid undesirable effects of large doses of Botox. The selection of this dose was similar to Polo⁽⁴⁾ and Hwang et al⁽⁵⁾. While Sucupria and Abramovitz in 2012⁽⁴⁰⁾ recommended a dose of 3U at each Yonsei point, and Jaspers et al⁽³⁹⁾ stated that a dose of 4U/side was acceptable.

For GD our results showed that the mean value of GD at baseline was 4.67 ± 0.88 mm and decreased to 0.52 ± 0.48 mm after one month of BTX-A injection, the effect of BTX-A injection may be due to that BTX-A injection intramuscularly produces partial chemical denervation of the muscle resulting in localized reduction of muscle activity, our results were similar to the many authors^(15,34-36). While after 4 months of BTX-A injection a slight increase in the amount of GD 1.61 ± 0.77 mm had been noticed but still with high significant differences with baseline. This slight increase may be due to that the effect of BTX-A injection dose begins to decrease. These results of reduction and then addition of the amount of GD were similar to Polo⁽³⁰⁾, Jaspers et al⁽³⁹⁾ and others^(5,31,33). Other studies reported that after 6 months of treatment of GS by BTX-A injection, complete relapse was noticed and the effect of BTX-A injection had been disappeared^(5,30-32,39).

Finally, our results showed no statistically significant differences between the two treatment modalities after 1 and 4 months of treatment procedures and this may be due to that both procedures were effective in the treatment of EGD.

Conclusions

Both MLRS and BTX-A injection were effective treatment methods for patients with EGD. Preference of one of them over the other completely depended on the causative factors of EGD and the patient's opinion after being informed about each procedure in detail such as their possible benefits, adverse effects, risks and the predictable duration of the result. Further studies with longer follow up are necessary.

References

1. Ker AJ, Chan R, Fields HW, Beck M, Rosenstiel S. Esthetics and smile characteristics from the lay person's perspective: a computer-based survey study. *J Am Dent Assoc.* 2008;139(10):1318–27.
2. Patel, Thakkar SA, Suthar JR. Adjunctive treatment of gummy smile using botulinum toxin Type-A (case report). *J Dent Med Sci.* 2012;3(1):22–9.
3. Van der Geld P, Oosterveld P, Van Heck G, Kuijpers-Jagtman AM. Smile attractiveness. Self-perception and influence on personality. *Angle Orthod.* 2007;77(5):759–65.
4. Polo M. Botulinum toxin type A (Botox) for the neuromuscular correction of excessive gingival display on smiling (gummy smile). *Am J Orthod Dentofac Orthop Off Publ Am Assoc Orthod Its Const Soc Am Board Orthod.* 2008;133(2):195–203.
5. Hwang W-S, Hur M-S, Hu K-S, Song W-C, Koh K-S, Baik H-S, et al. Surface anatomy of the lip elevator muscles for the treatment of gummy smile using botulinum toxin. *Angle Orthod.* 2009;79(1):70–7.
6. Rosenblatt A, Simon Z. Lip repositioning for reduction of excessive gingival display: a clinical report. *Int J Periodontics Restorative Dent.* 2006;26(5):433–7.
7. Kokich VO, Kiyak HA, Shapiro PA. Comparing the perception of dentists and lay people to altered dental esthetics. *J Esthet Dent.* 1999;11(6):311–24.
8. Garber DA, Salama MA. The aesthetic smile: diagnosis and treatment. *Periodontol 2000.* 1996;11:18–28.
9. Bhola M, Fairbairn PJ, Kolhatkar S, Chu SJ, Morris T, de Campos M. LipStaT: the lip stabilization technique- indications and guidelines for case selection and classification of excessive gingival display. *Int J Periodontics Restorative Dent.* 2015;35(4):549–59.
10. Silberberg N, Goldstein M, Smidt A. Excessive gingival display--etiology, diagnosis, and treatment modalities. *Quintessence Int Berl Ger.* 2009;40(10):809–18.
11. Peck S, Peck L, Kataja M. The gingival smile line. *Angle Orthod.* 1992;62(2):91–100.
12. Fish LC, Epker BN, Sullivan CR. Orthognathic surgery: the correction of dentofacial deformities. *J Oral Maxillofac Surg Off J Am Assoc Oral Maxillofac Surg.* 1993;51(1 Suppl 1):28–41.
13. Gupta KK, Srivastava A, Singhal R, Srivastava S. An innovative cosmetic

- technique called lip repositioning. *J Indian Soc Periodontol.* 2010;14(4):266–9.
14. Srivastava S, Kharbanda S, Pal US, Shah V. Applications of botulinum toxin in dentistry: A comprehensive review. *Natl J Maxillofac Surg.* 2015;6(2):152–9.
 15. Miskinyar SA. A new method for correcting a gummy smile. *Plast Reconstr Surg.* 1983;72:397–400.
 16. Makkiah MO. Assessment of the efficiency of botox and lip reposition in the correction of the gummy smile according to the patients' satisfaction. *Oral Health Dental Sci.* 2017; 1(1): 1-4.
 17. Dayakar MM, Gupta S, Shivananda H. Lip repositioning: An alternative cosmetic treatment for gummy smile. *J Indian Soc Periodontol.* 2014;18(4):520–3.
 18. Vyas. *Clinical Photography in Dentistry.* 1 edition. New Delhi: Jaypee Brothers Medical Publishers Private Limited; 2008. 112 p.
 19. Nigam PK, Nigam A. Botulinum toxin. *Indian J Dermatol.* 2010;1:55(1):8.
 20. Silva CO, Ribeiro-Júnior NV, Campos TVS, Rodrigues JG, Tatakis DN. Excessive gingival display: treatment by a modified lip repositioning technique. *J Clin Periodontol.* 2013;40(3):260–5.
 21. Roe P, Runcharassaeng K, Kan J, Patel R, Campagni W, Brudvik J. The influence of upper lip length and lip mobility on maxillary incisal exposure. *Am J Esthet Dent.* 2012 1;2:116–25.
 22. Allen EP. Use of mucogingival surgical procedures to enhance esthetics. *Dent Clin North Am.* 1988;32(2):307–30.
 23. Carruthers A, Carruthers J. Prospective, double-blind, randomized, parallel-group, dose-ranging study of botulinum toxin type A in men with glabellar rhytids. *Dermatol Surg Off Publ Am Soc Dermatol Surg Al.* 2005;31(10):1297–303.
 24. Carruthers A, Carruthers J, Flynn TC, Leong MS. Dose-finding, safety, and tolerability study of botulinum toxin type B for the treatment of hyperfunctional glabellar lines. *Dermatol Surg Off Publ Am Soc Dermatol Surg Al.* 2007;33(1 Spec No.):S60–68.
 25. Litton C, Fournier P. Simple surgical correction of the gummy smile. *Plast Reconstr Surg.* 1979;63(3):372–3.
 26. Simon Z, Roseblatt A, Dorfman W. Eliminating a gummy smile with surgical lip repositioning. *Cosmet Dent.* 2007;23(1):100–8.
 27. Grover HS, Gupta A, Luthra S. Lip repositioning surgery: A pioneering technique for perio-esthetics. *Contemp Clin Dent.* 2014;5(1):142–5.
 28. Gaddale R, Desai SR, Mudda JA, Karthikeyan I. Lip repositioning. *J Indian Soc Periodontol.* 2014;18(2):254.
 29. Pandey V. Correction of gummy smiles with botulinum toxin case report and review. *J Adv Med Dent Sci Res.* 2014;2(3):137–41.
 30. Polo M. Botulinum toxin type A in the treatment of excessive gingival display. *Am J Orthod Dentofac Orthop Off Publ Am Assoc Orthod Its Const Soc Am Board Orthod.* 2005;127(2):214–8.
 31. Suber JS, Dinh TP, Prince MD, Smith PD. Onabotulinumtoxin A for the treatment of a “gummy smile.” *Aesthet Surg J.* 2014;34(3):432–7.
 32. Dinker S, Anitha A, Sorake A, Kumar K. Management of gummy smile with Botulinum toxin type-A: A case report. *J Int Oral Health JIOH.* 2014;6(1):111–5.
 33. Rao AG, Koganti VP, Prabhakar AK, Soni S. Modified lip repositioning: A surgical approach to treat the gummy smile. *J Indian Soc Periodontol.* 2015;19(3):356.
 34. Dannan A, Al Saraf I. Treatment of gummy smile appearance using the modified lip repositioning technique: A pilot study. *JBR J Interdiscip Med Dent Sci.* 2017;5(3):1–4.
 35. Mantovani MB, Souza EC, Marson FC, Corrêa GO, Progiante PS, Silva CO. Use of modified lip repositioning technique associated with esthetic crown lengthening for treatment of excessive gingival display:

- A case report of multiple etiologies. *J Indian Soc Periodontol.* 2016;20(1):82–7.
36. Ribeiro-Júnior NV, Campos TV de S, Rodrigues JG, Martins TMA, Silva CO. Treatment of excessive gingival display using a modified lip repositioning technique. *Int J Periodontics Restorative Dent.* 2013;33(3):309–14.
 37. Sánchez IM, Gaud-Quintana S, Stern JK. Modified lip repositioning with esthetic crown lengthening: a combined approach to treating excessive gingival display. *Int J Periodontics Restorative Dent.* 2017;37(1):e130–4.
 38. Humayun N, Kolhatkar S, Souiyas J, Bhola M. Mucosal coronally positioned flap for the management of excessive gingival display in the presence of hypermobility of the upper lip and vertical maxillary excess: a case report. *J Periodontol.* 2010;81(12):1858–63.
 39. Jaspers GWC, Pijpe J, Jansma J. The use of botulinum toxin type A in cosmetic facial procedures. *Int J Oral Maxillofac Surg.* 2011;40(2):127–33.
 40. Sucupira E, Abramovitz A. A simplified method for smile enhancement: botulinum toxin injection for gummy smile. *Plast Reconstr Surg.* 2012;130(3):726–8.